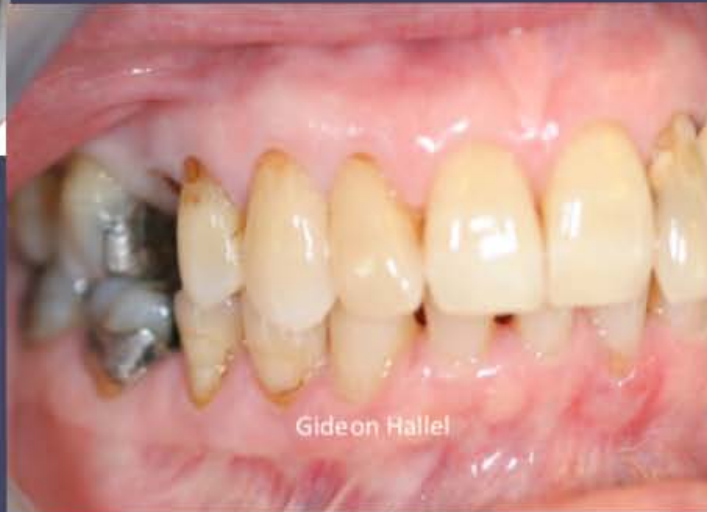
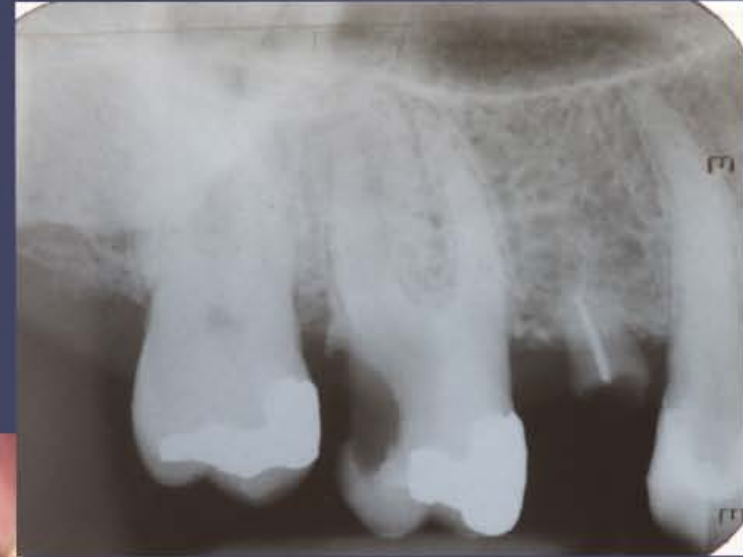
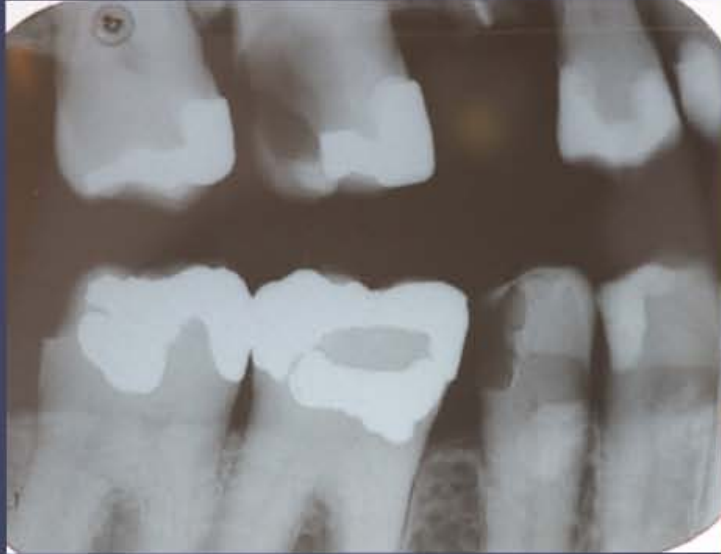Implant in a grinded  
dentin preserved  
molar socket  
5.5 years follow up

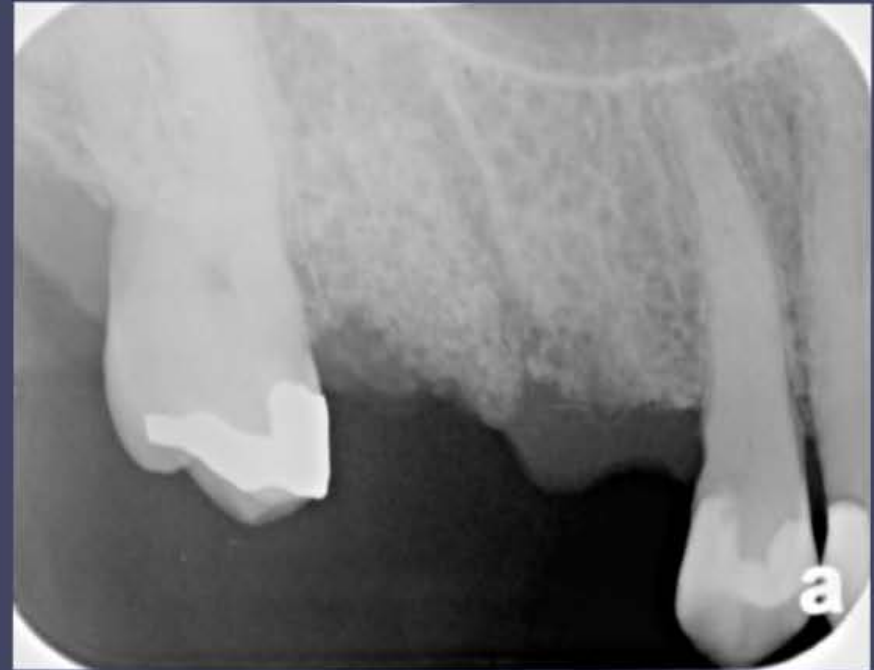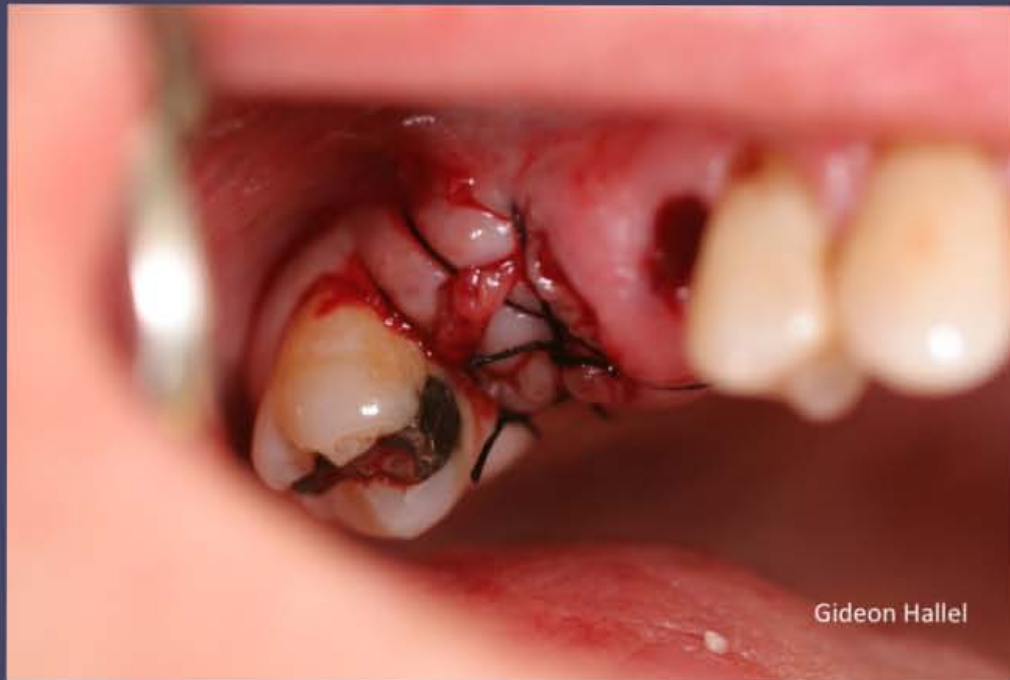Gideon Hallel DMD MPA

[info@drhallel.com](mailto:info@drhallel.com)

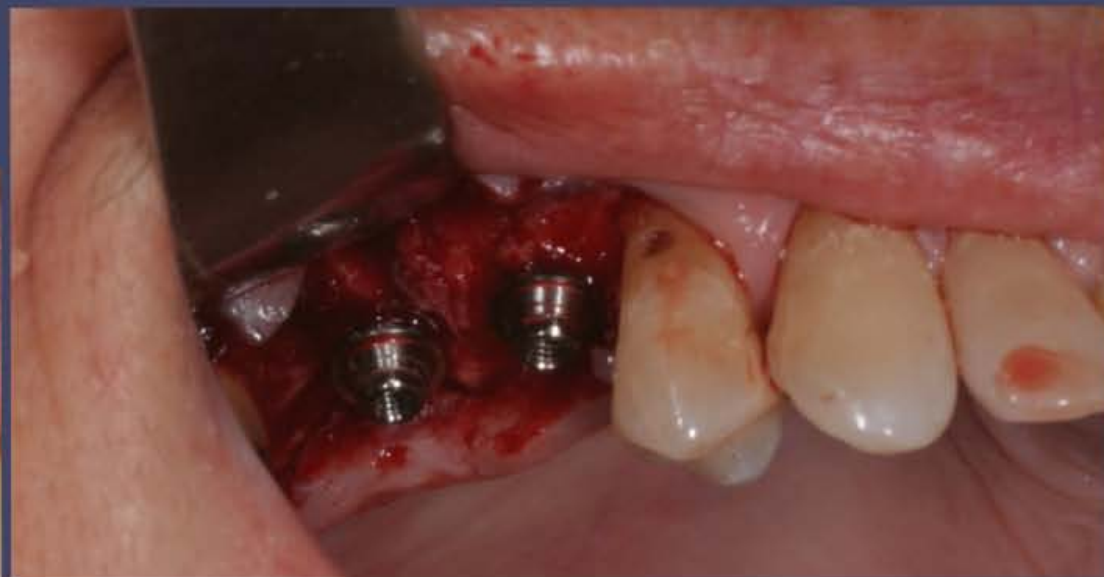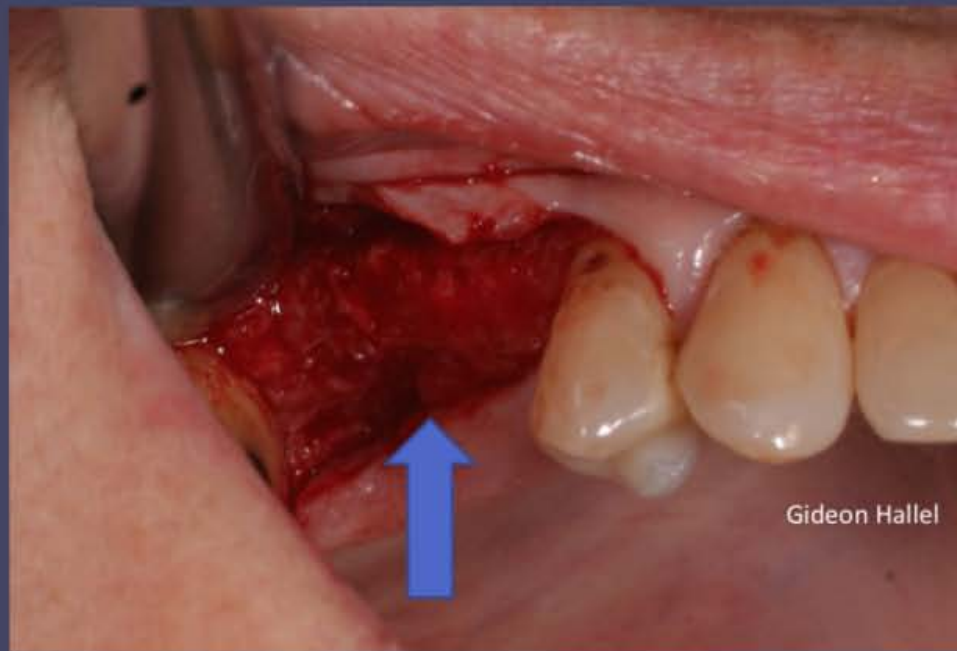
# Pre – op 2013

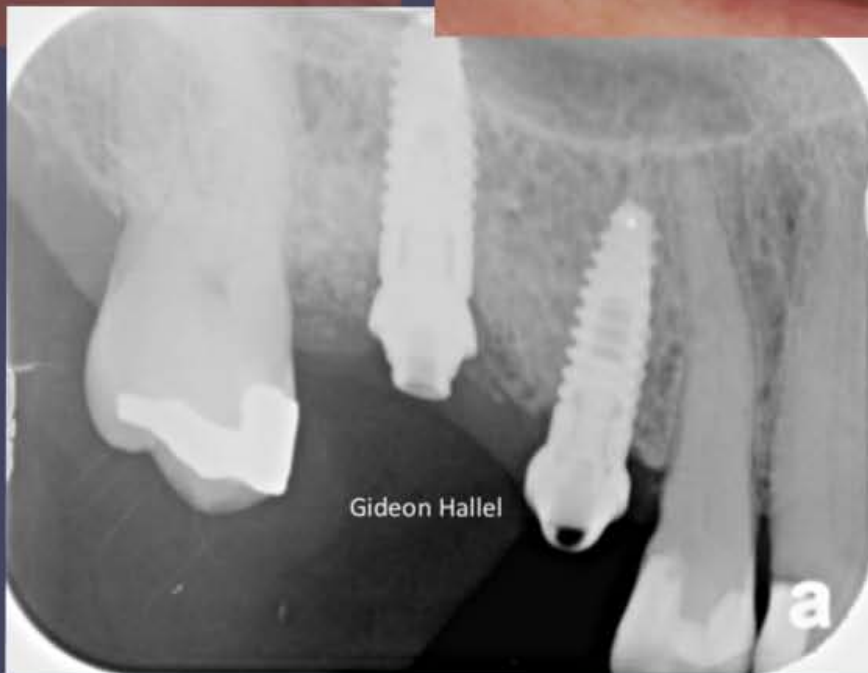
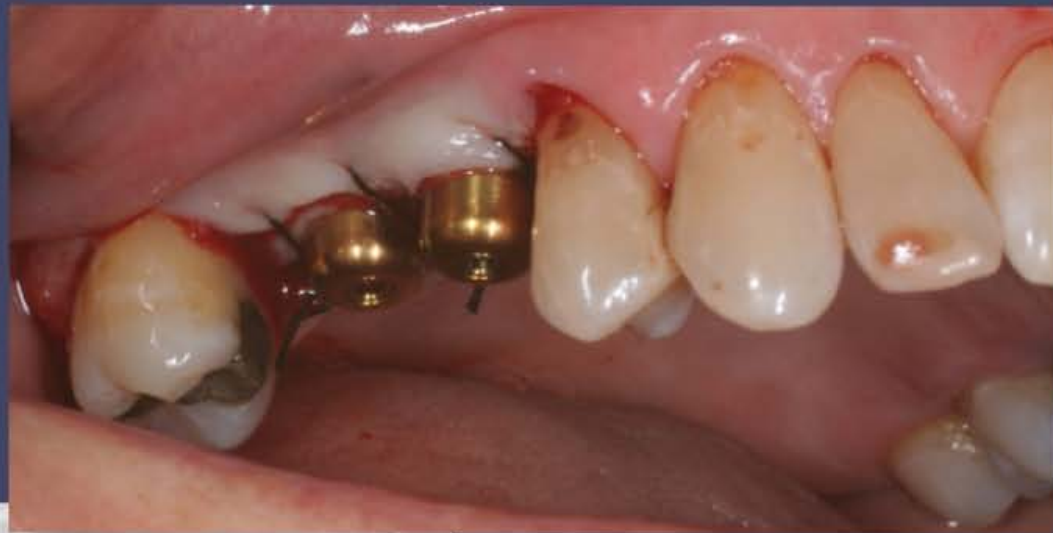
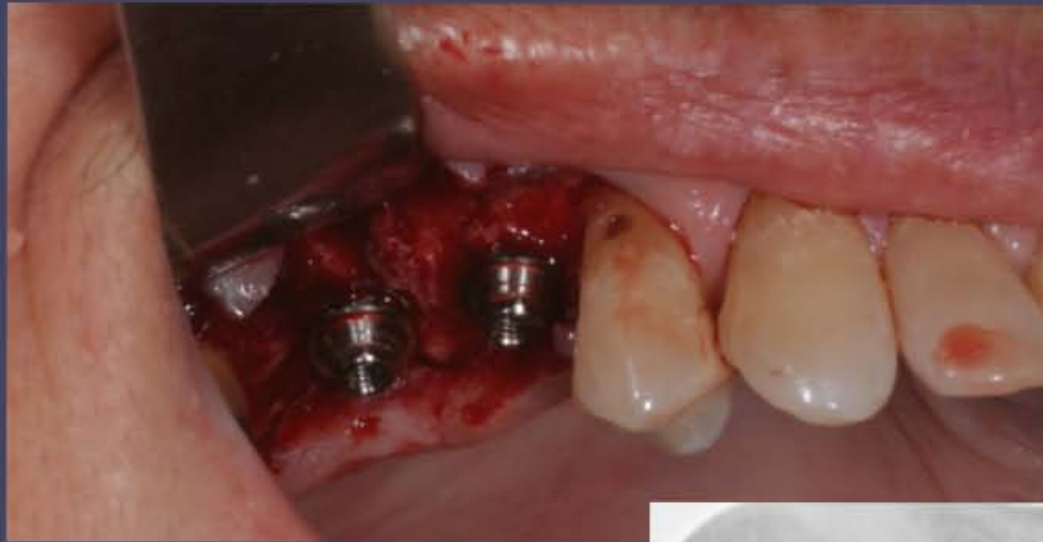# Socket preservation with dentin jan 2014 (no membrane) .

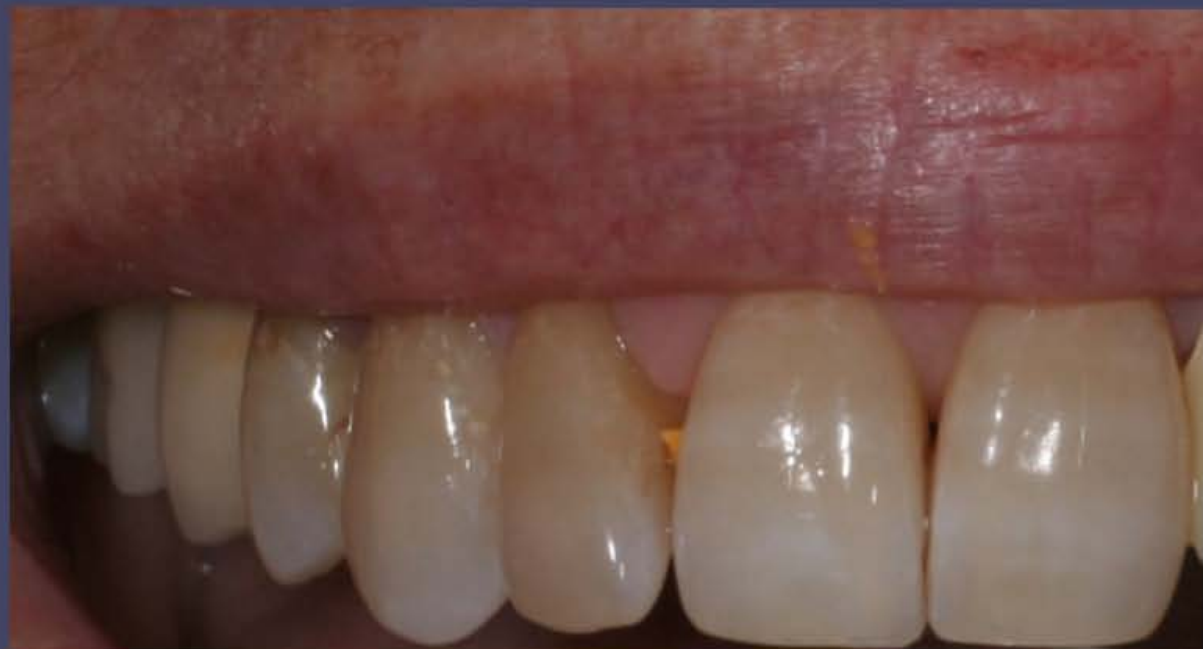
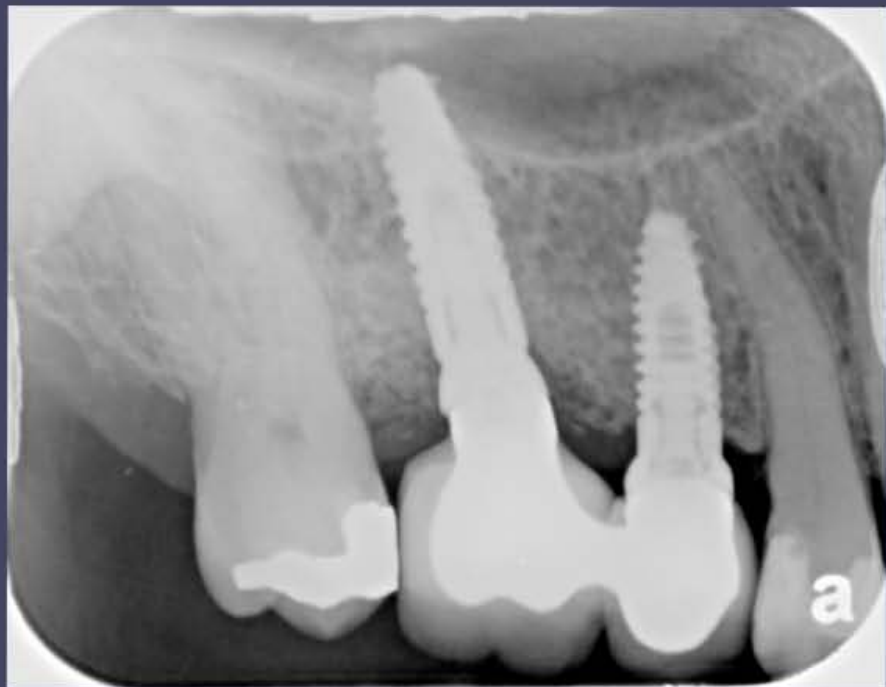
implants insertion after 3 months, note  
dentin particles mar. 2014

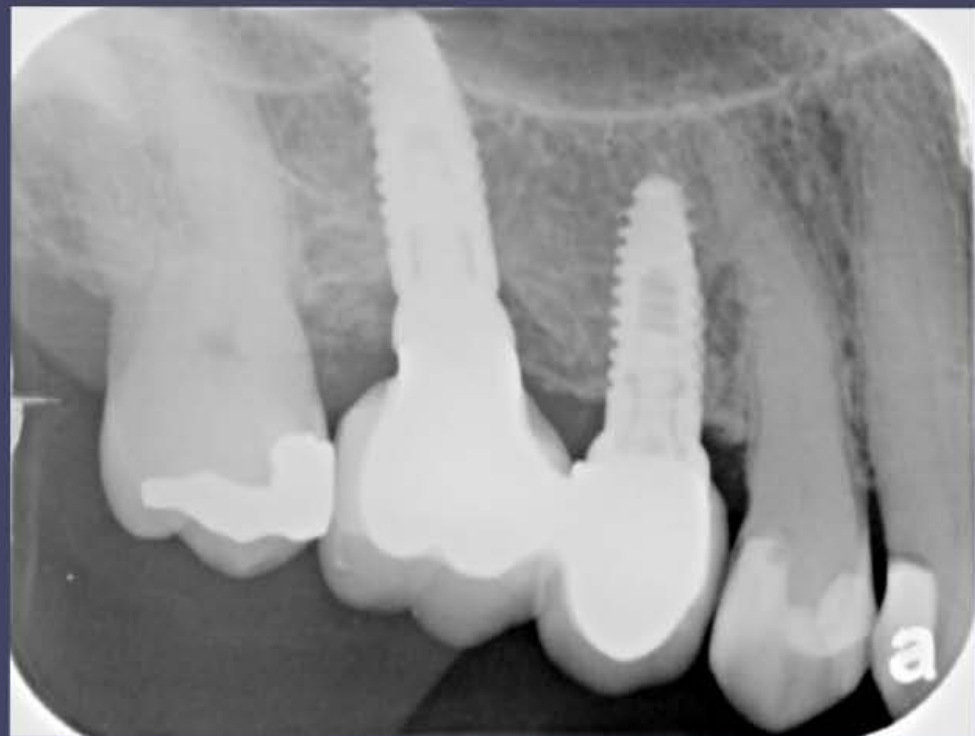



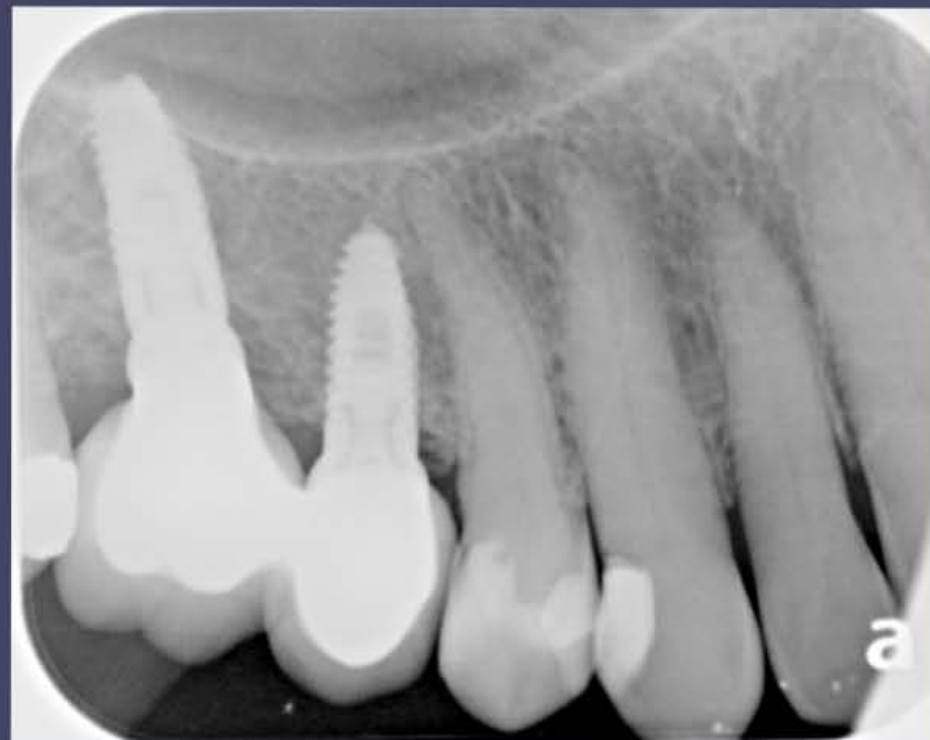# Final crowns on multi units jul. 2014



Aug 2015

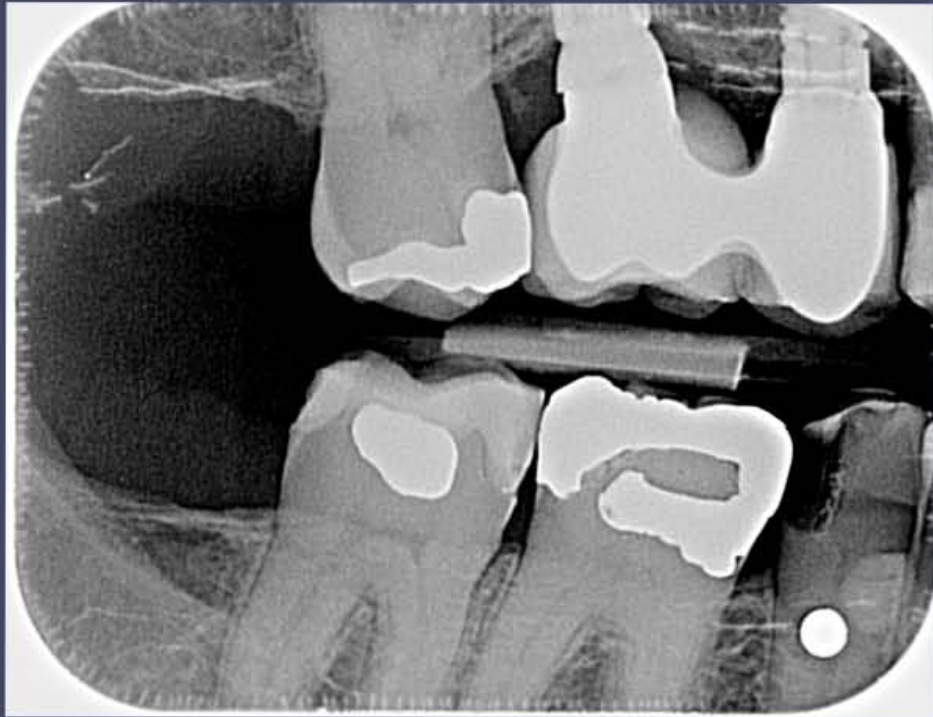

Jun 2017

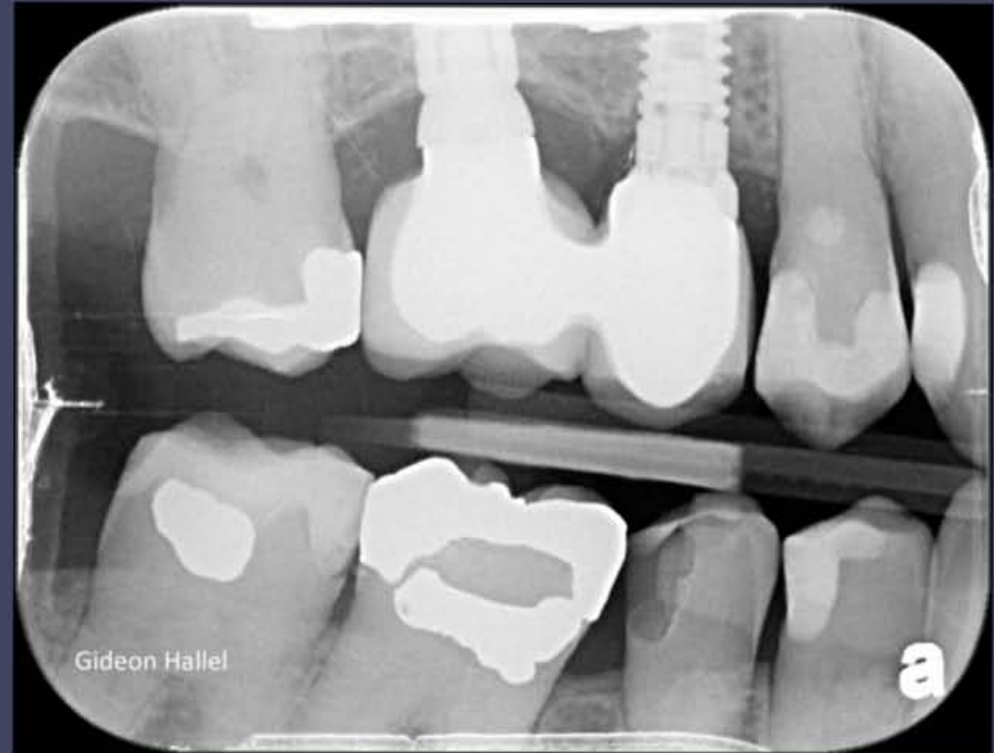

# Bite wing comparison

Jun 2017

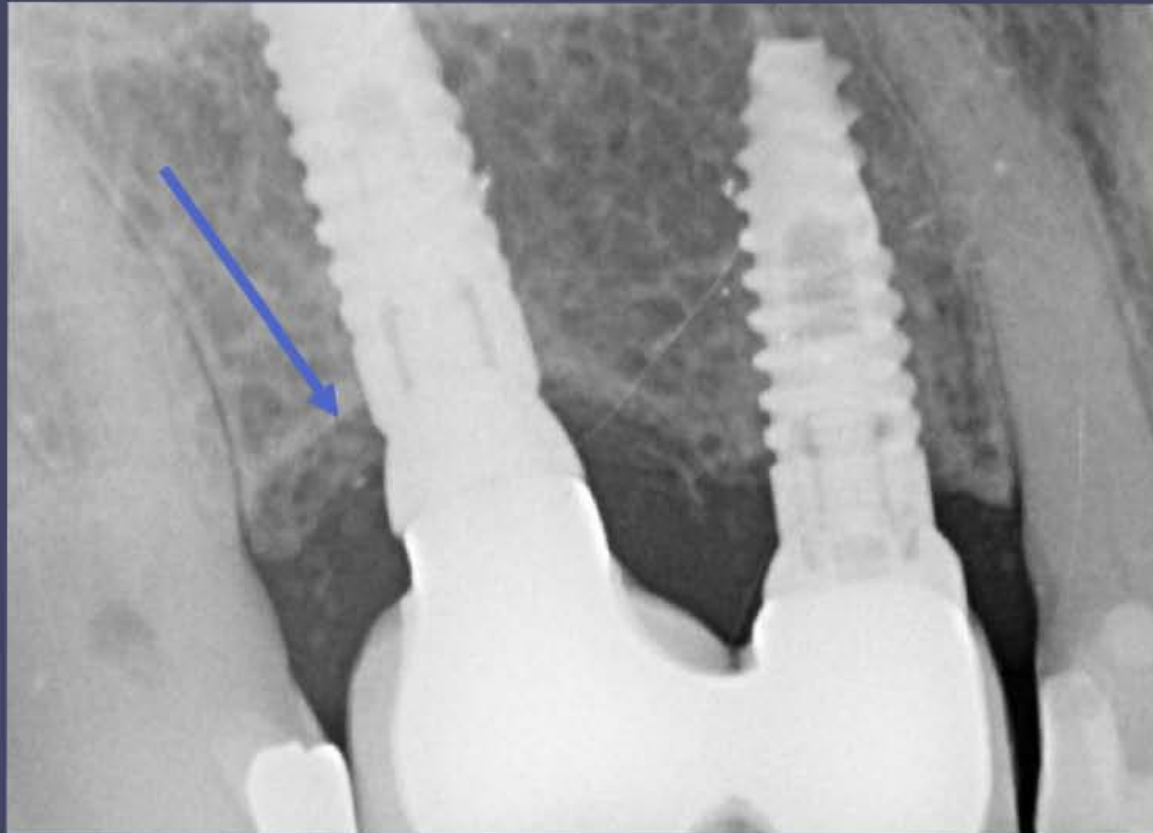
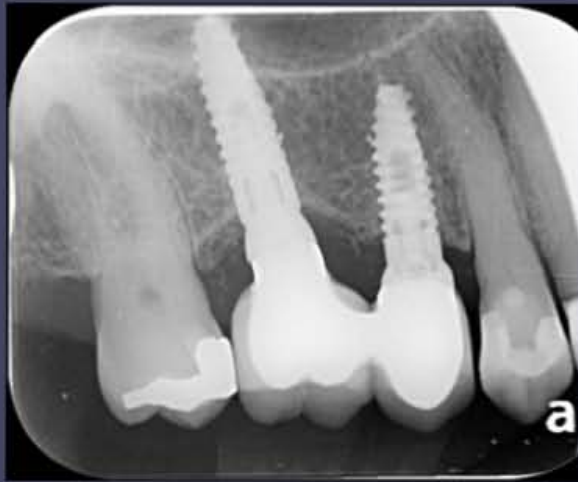

Sep 2019





# Sep 2019 note dentin maturation



# Dentin maturation 2014 – 2019

